


PRESENTING CLINICAL SIGNS

DATE History: Grade III/VI systolic murmur. Recently coughing. Pre-anesthetic evaluation (dental).

ECHOCARDIOGRAPHIC FINDINGS

2D, M-mode, and Doppler study.

PERFORMED BY: Left atrial size is normal. The mitral valve leaflets are mildly thickened, and there is Doppler evidence of mitral regurgitation present. Left ventricular dimensions are normal. Left ventricular systolic function is normal. The aorta and aortic valve are normal. Right atrial and right ventricular dimensions are normal. The tricuspid valve is normal. The pulmonary artery and pulmonic valve are normal. No pericardial effusion or cardiac masses are seen.

Shari Reffi, CVT

INTERPRETED BY

Keith Blass, DVM,
MS, DACVIM
(Cardiology)

LA - 44.6 mm
LVIDd - 40.5 mm
LVIDs - 27.2 mm
FS - 32.8%
RA - 34.1 mm
LVOT - 1.06 m/s
RVOT - 0.85 m/s

PATIENT

Bandit Elango

ASSESSMENT/RECOMMENDATIONS

Degenerative mitral valve disease

SPECIES

Canine

This examination demonstrates regurgitation of blood across Bandit's mitral valve resulting from degenerative valve disease. The hemodynamic effects of the regurgitation appear to be mild, as Bandit does not have secondary dilation of either of his left heart chambers, and his left ventricular systolic function is normal. As such, Bandit's mitral valve disease appears to be well-compensated, and it does not appear to be the cause of his cough.

BREED

Labrador Retriever

Bandit's cardiovascular risk for general anesthesia is mildly increased based on this exam, therefore, some precautions should be taken in order to minimize this risk. I recommend avoiding the use of alpha-2 agonists, ketamine, and telazol in the anesthetic protocol, as well as reducing the IV fluid rate by 25%. If possible, monitoring of heart rhythm, blood pressure, and pulse oximetry are recommended during the procedure.

SEX

MN

No therapy is recommended at this stage of disease.

AGE

11 y

A recheck echocardiogram is recommended in ~6 months to monitor for disease progression.

WEIGHT

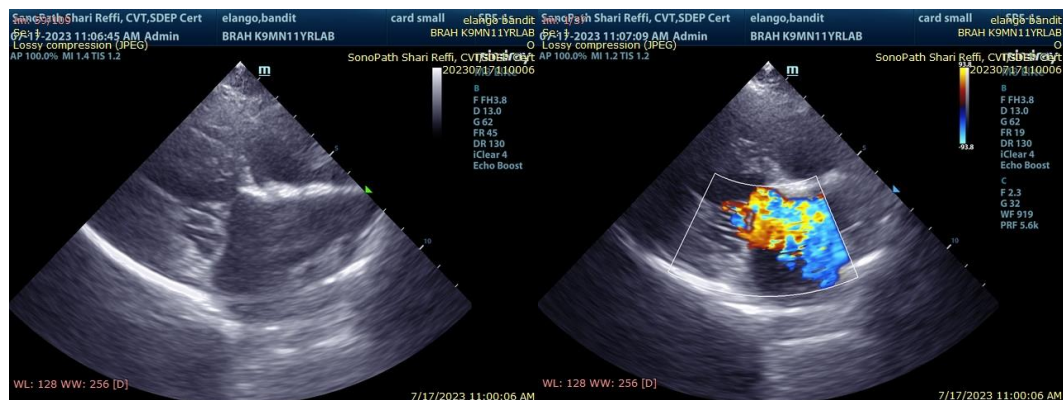
68 lb

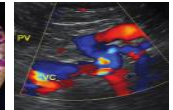
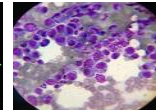
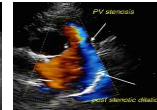
HOSPITAL NAME

Basking Ridge AH

REFERRING VET

Dr. Hollo





DATE

7/17/23

The information and recommendations provided are based on the images presented by the referring veterinarian. No evaluation can be communicated regarding pathology that was not visible in the image/video clips provided.

PERFORMED BY:

Shari Reffi, CVT

Thank you for this referral. If the clinical or image interpretation does not parallel your findings or if I can be of any further assistance please contact me.

INTERPRETED BY

Keith Blass, DVM,
MS, DACVIM
(Cardiology)

Keith Blass, DVM, MS, DACVIM (Cardiology)
KeithBlass@gmail.com
631-804-5754

PATIENT

Bandit Elango

SPECIES

Canine

BREED

Labrador Retriever

SEX

MN

AGE

11 y

WEIGHT

68 lb

HOSPITAL NAME

Basking Ridge AH

REFERRING VET

Dr. Hollo